

# VT or VPCs

충남대학교 병원 심장내과

김 준 형

# Case 1

- 43세 여자
- 10여 년 전부터 지속된 심계항진
- 증상 악화되어 개인의원에서 전원
- 여호와의 증인

# 홀터검사

Patient name: SEON HAE LEE  
Patient ID: 1474561  
Site: ChungNam National Univ. Hospital

## HOLTER REPORT

### PATIENT and STUDY INFORMATION

Patient name: SEON HAE LEE	Study date: 31-Aug-2015
Patient ID: 1474561	Referring MD:
DoB/Age: 43 Years	Ordering MD:
Gender: Female	Technician:
Medications:	

### REASON for STUDY

#### Indications:

#### BEAT COUNTS

QRS complexes: 115066

Paced: 0

Ventricular ectopics: 40468 35% of QRS complexes

Supraventricular ectopics: 46 < 1% of QRS complexes

#### HEART RATES

Minimum: 33 at: 00:38:14 01-Sep-2015

Maximum: 122 at: 09:07:20 01-Sep-2015

Average: 55

### VENTRICULAR ECTOPY

Isolated: 38030 5 beats LONGEST at: 165bpm 09:45:10 01-Sep-2015

Couplets: 1098 3 beats FASTEST at: 174bpm 21:45:23 31-Aug-2015

Runs: 78

Total beats: 242

Bigeminal: 25882

### SUPRAVENTRICULAR ECTOPY

Isolated: 36 beats LONGEST at: bpm

Couplets: 5 beats FASTEST at: bpm

Runs: 0

Total beats: 0

Longest RR: 2.368 sec at: 00:26:50 01-Sep-2015

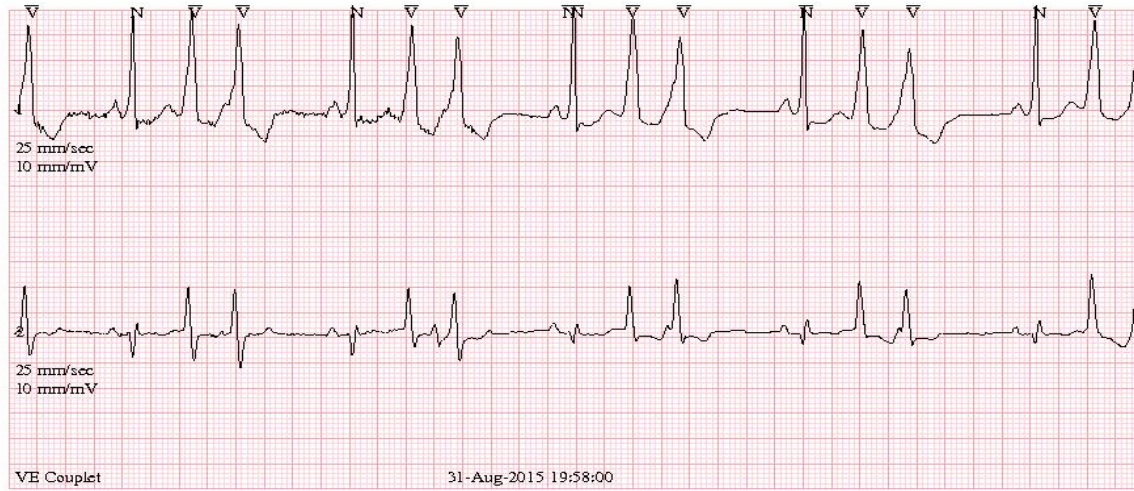
Acq duration: 23:09

### INTERPRETATION

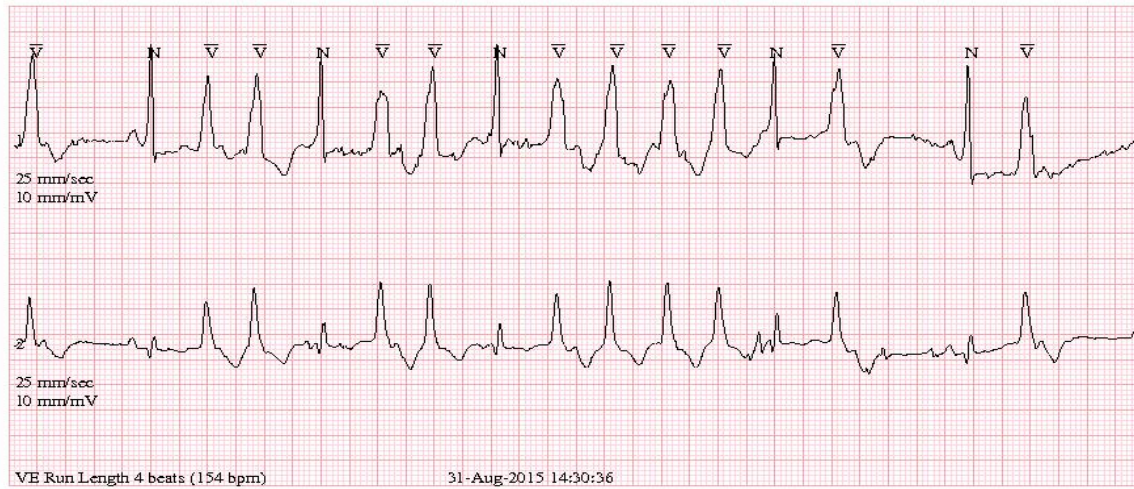
Finding) 1) VPB (35%) 2) Nonsustained VT (longest 5beat)

Conclusion)

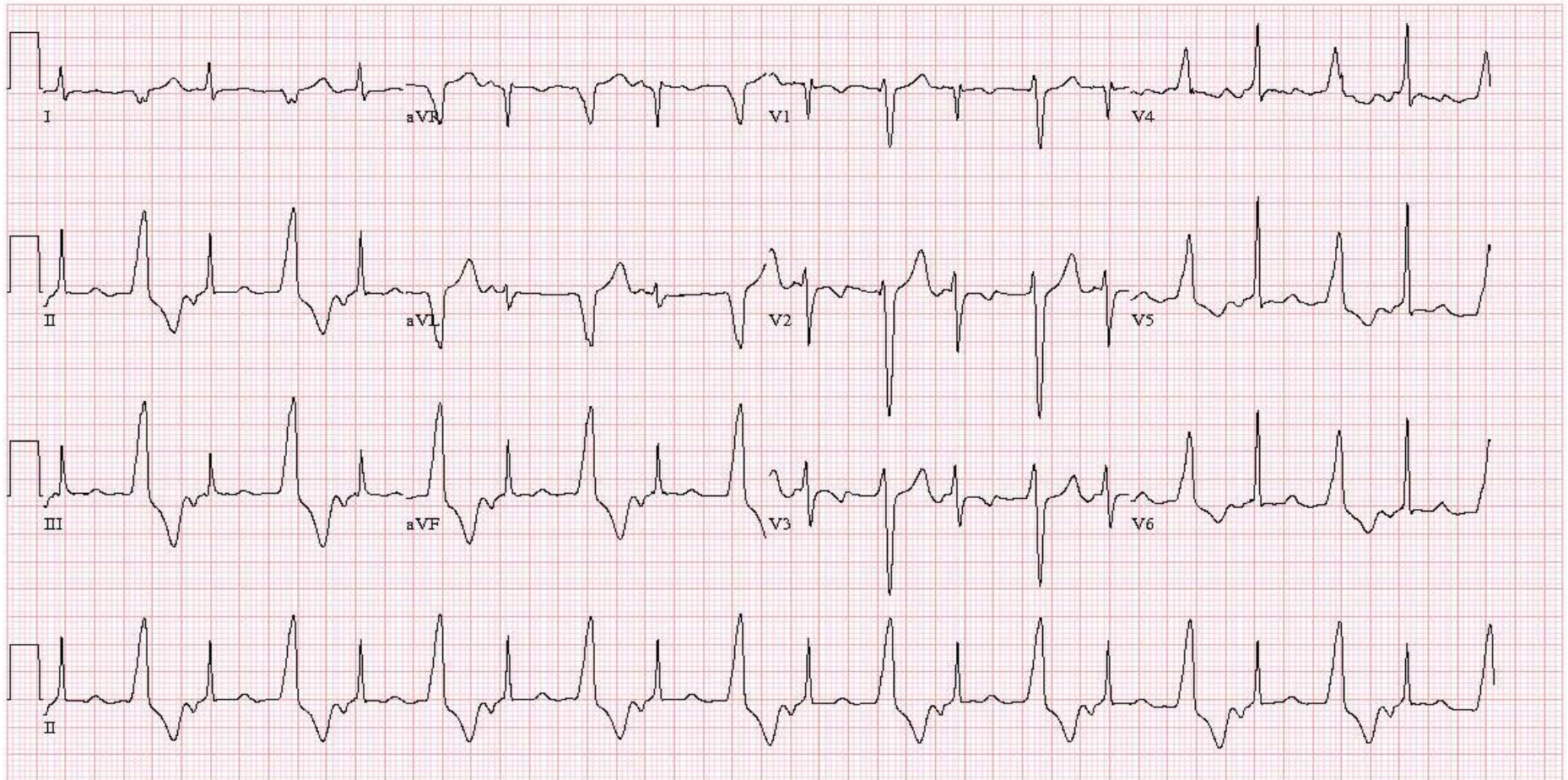
Minimum R-R



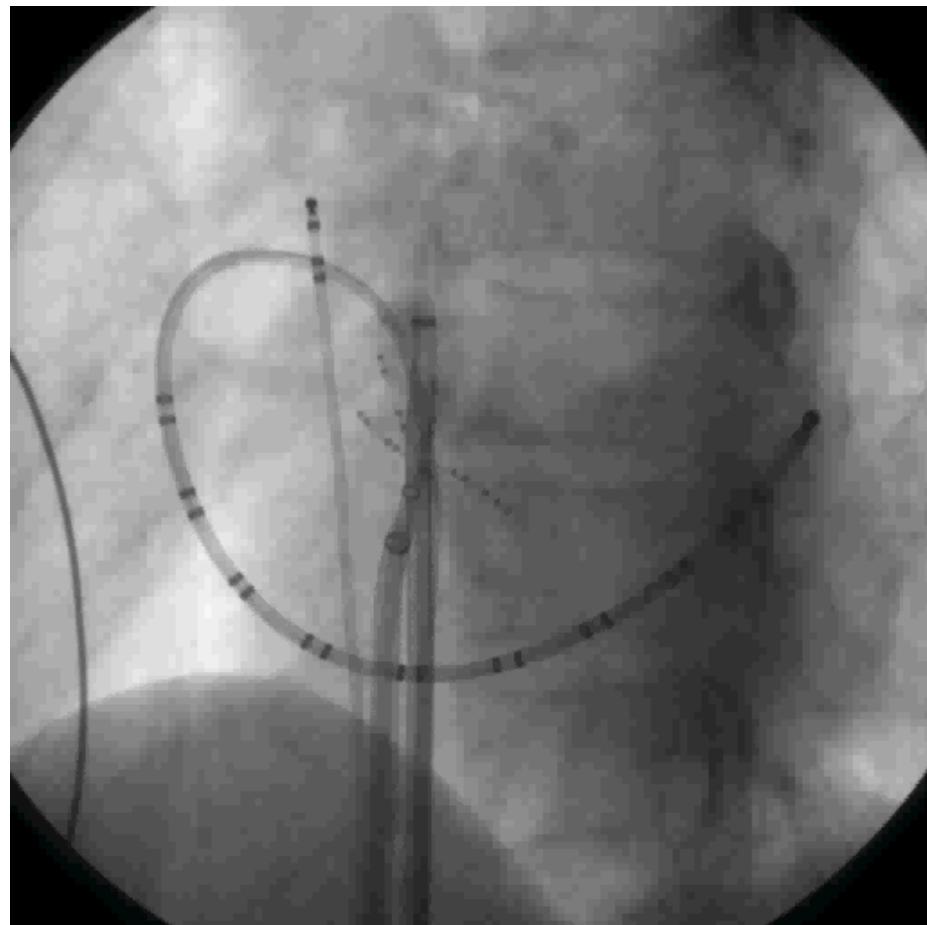
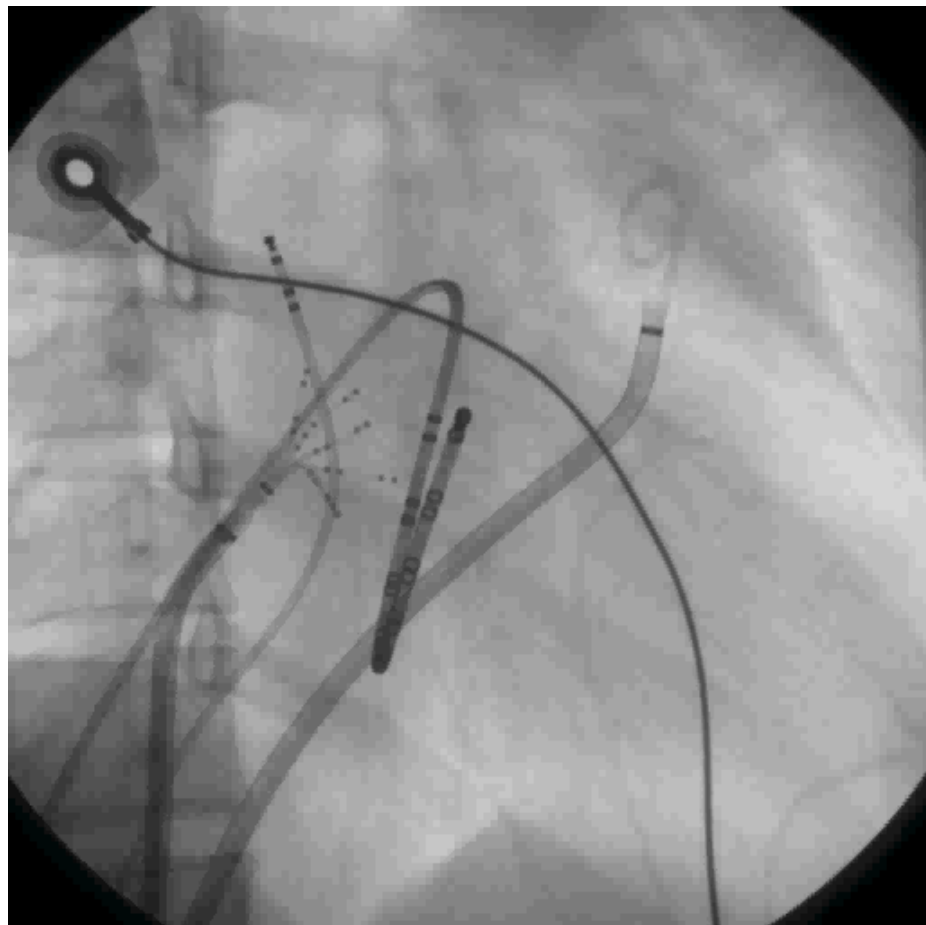
Nonsustained VT








# RVOT angio





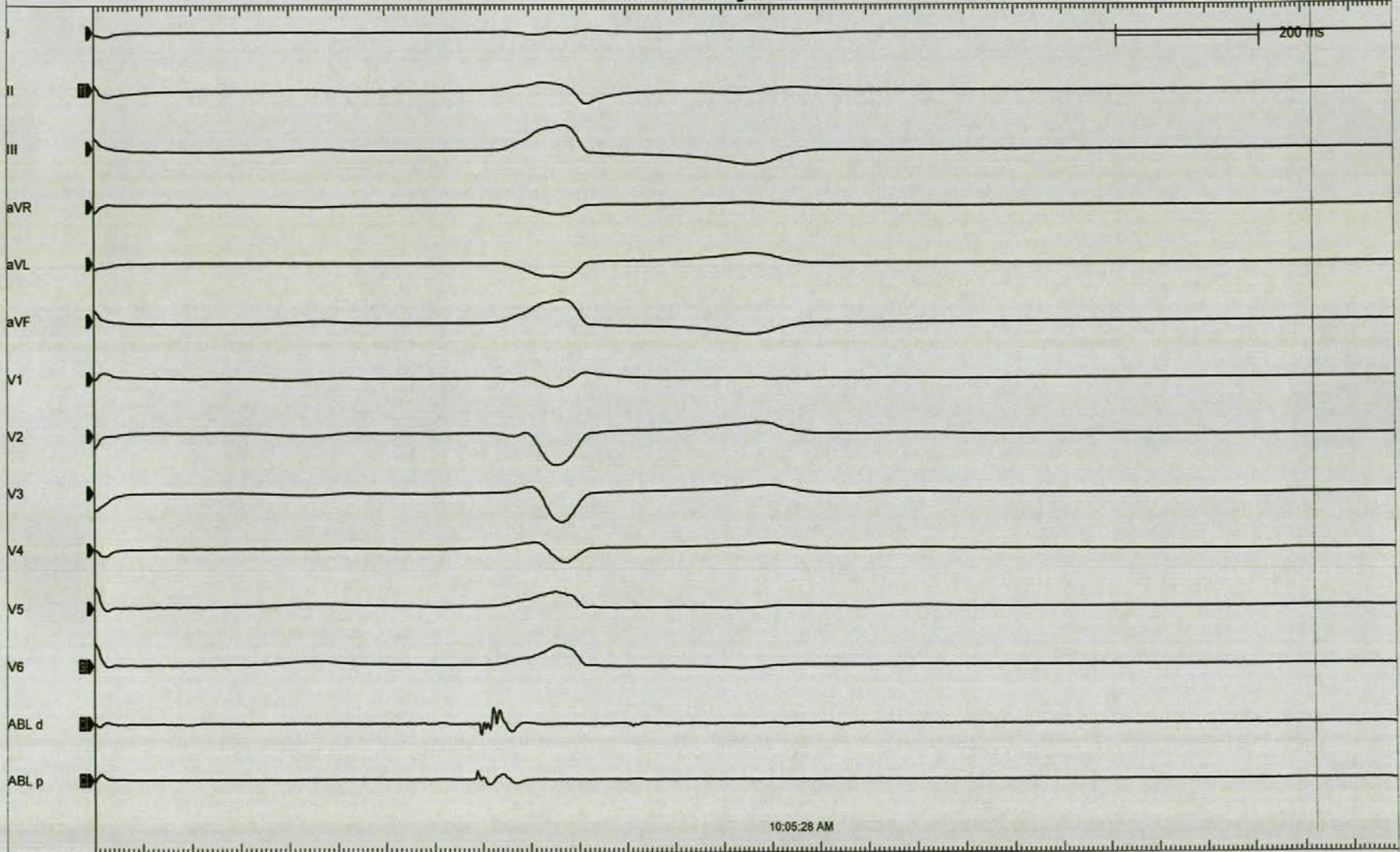
VPC1

200 ms



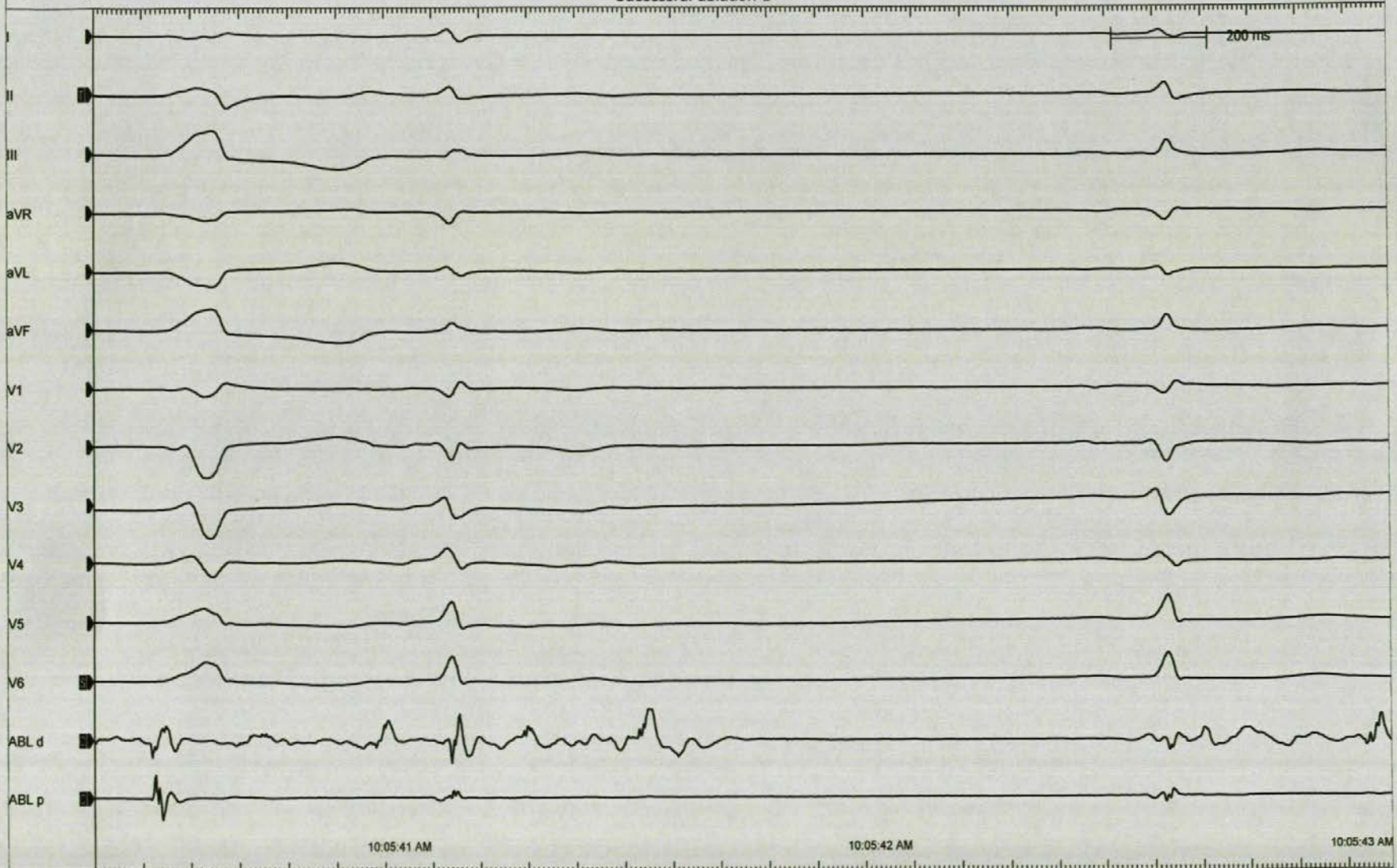
8:31:01 AM

Good ablation signal 1





Successful ablation 1

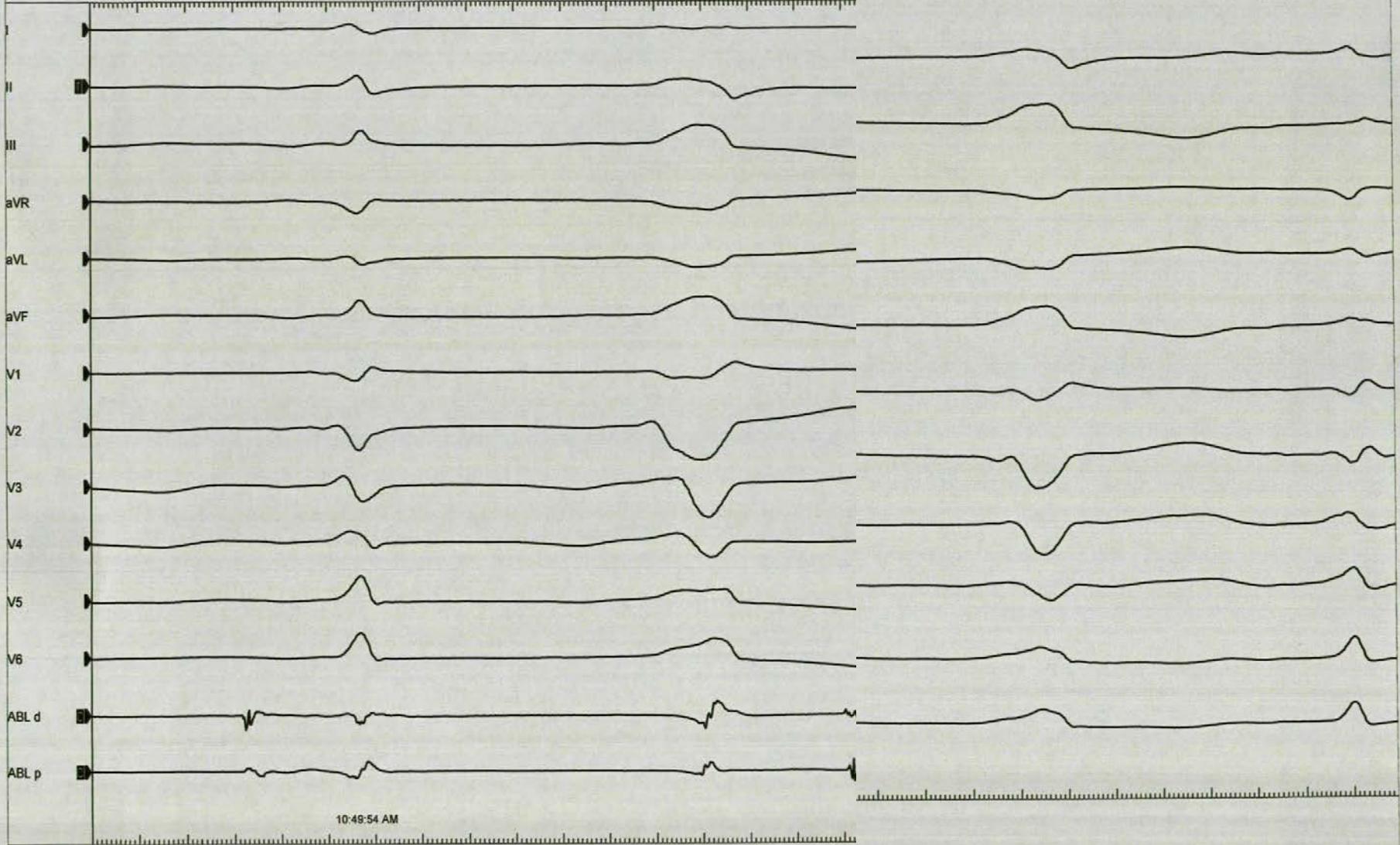


11/17/2019 10:49:54 AM (Speed: 250 mm/s)  
01474561

VPC 1

VPC2 + isuprel

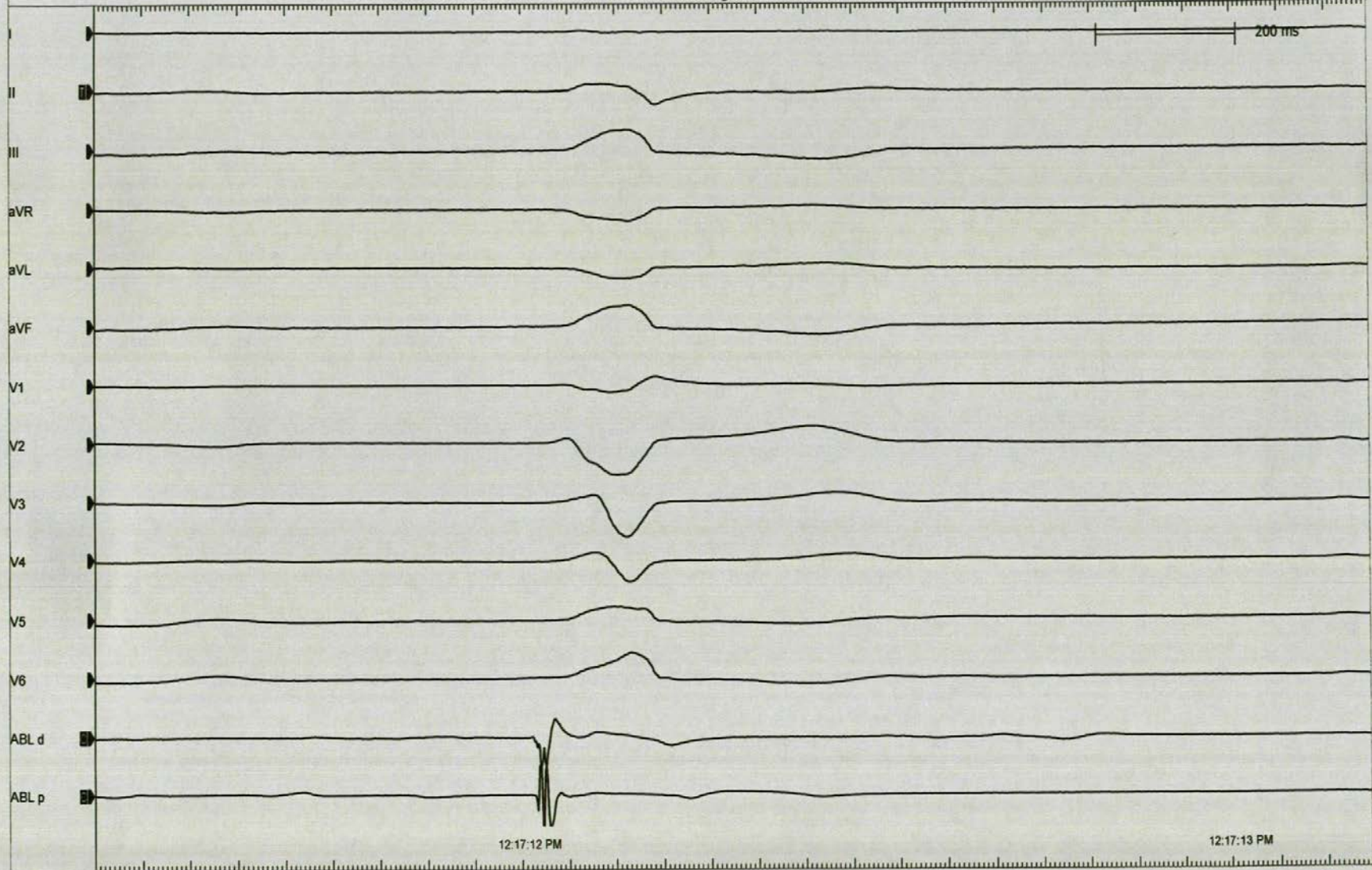
200 ms





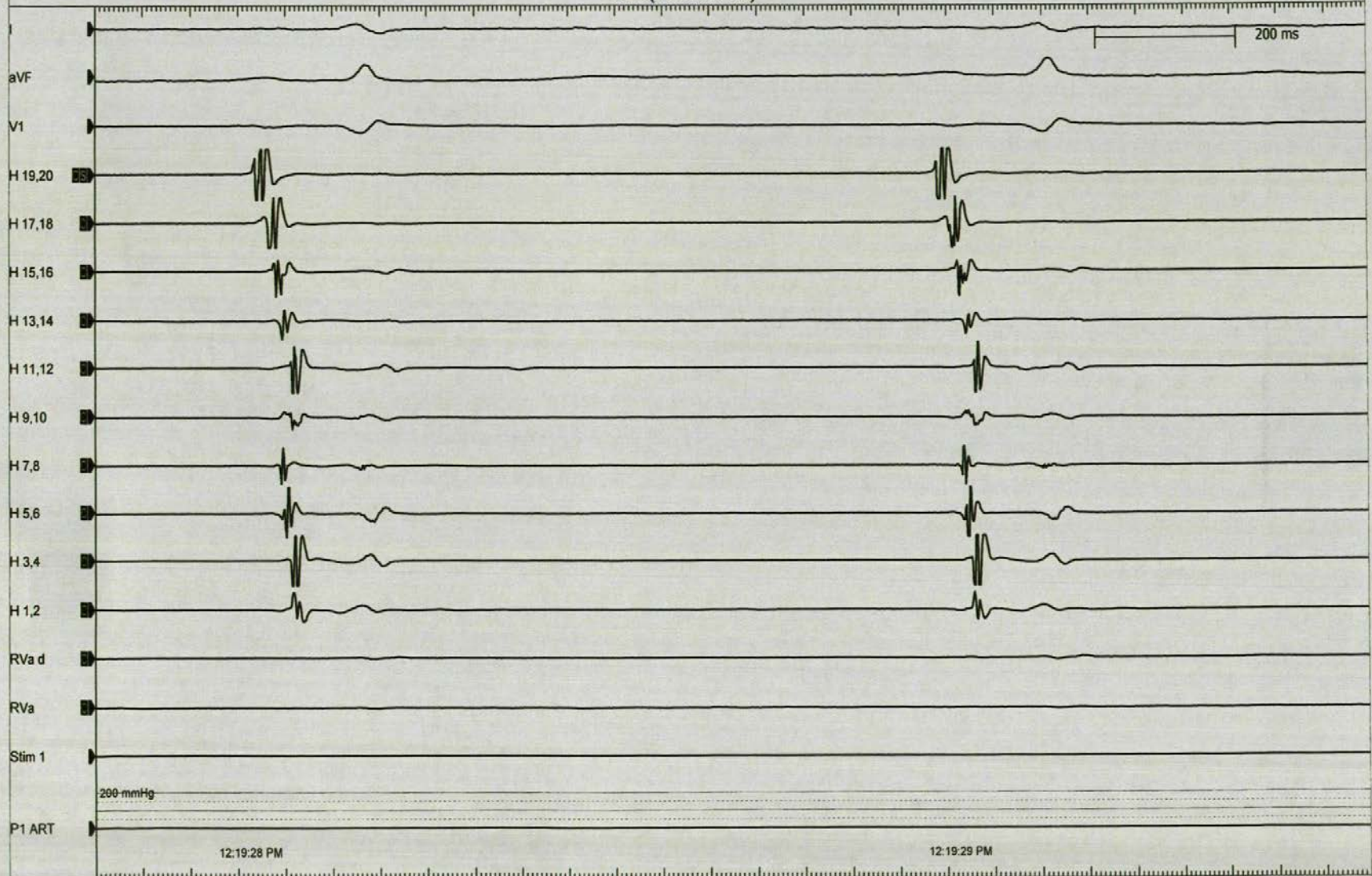
Good ablation signal 2

200 ms

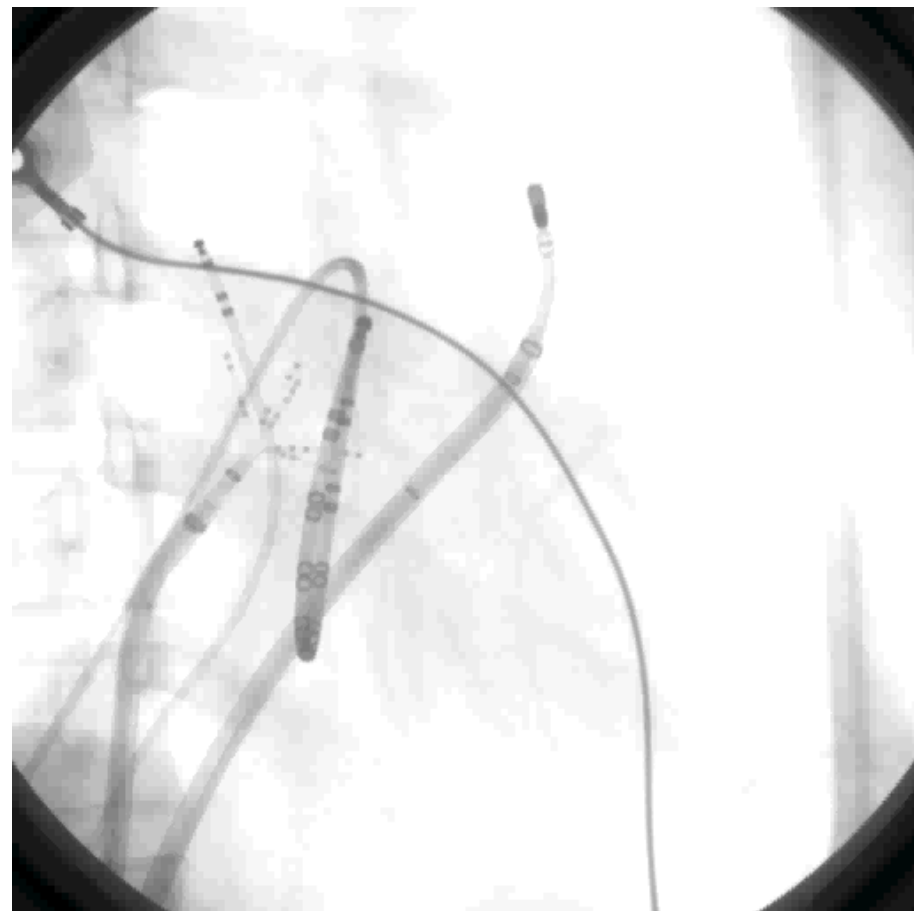
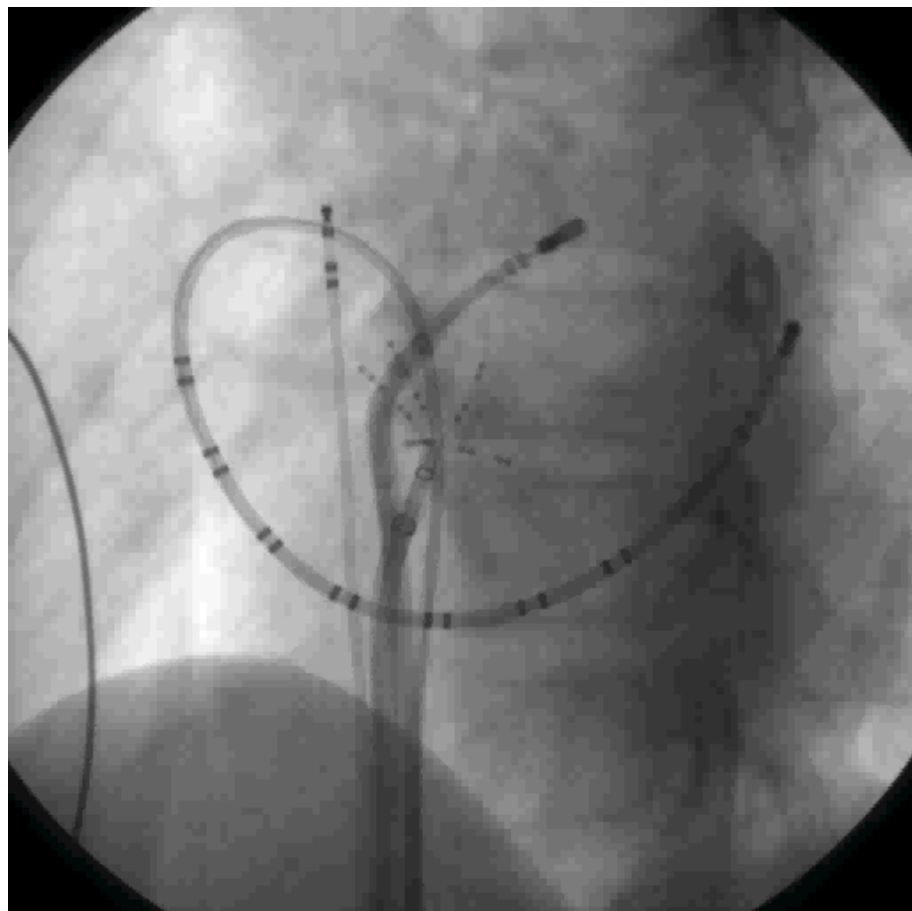




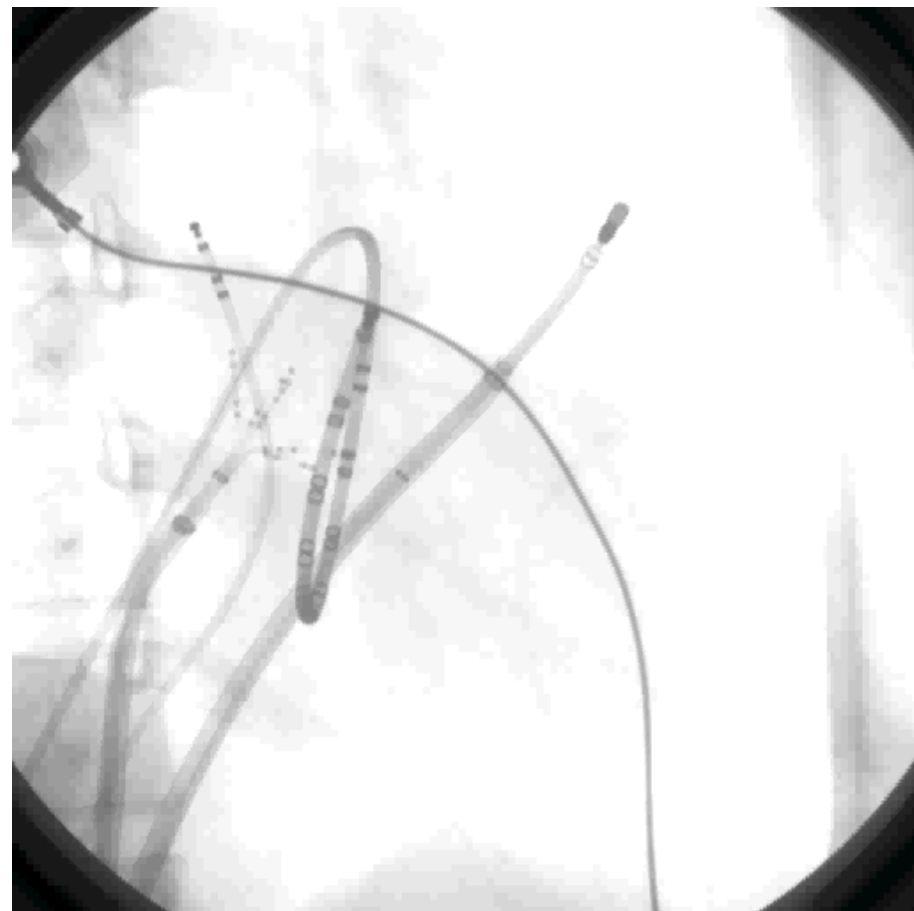
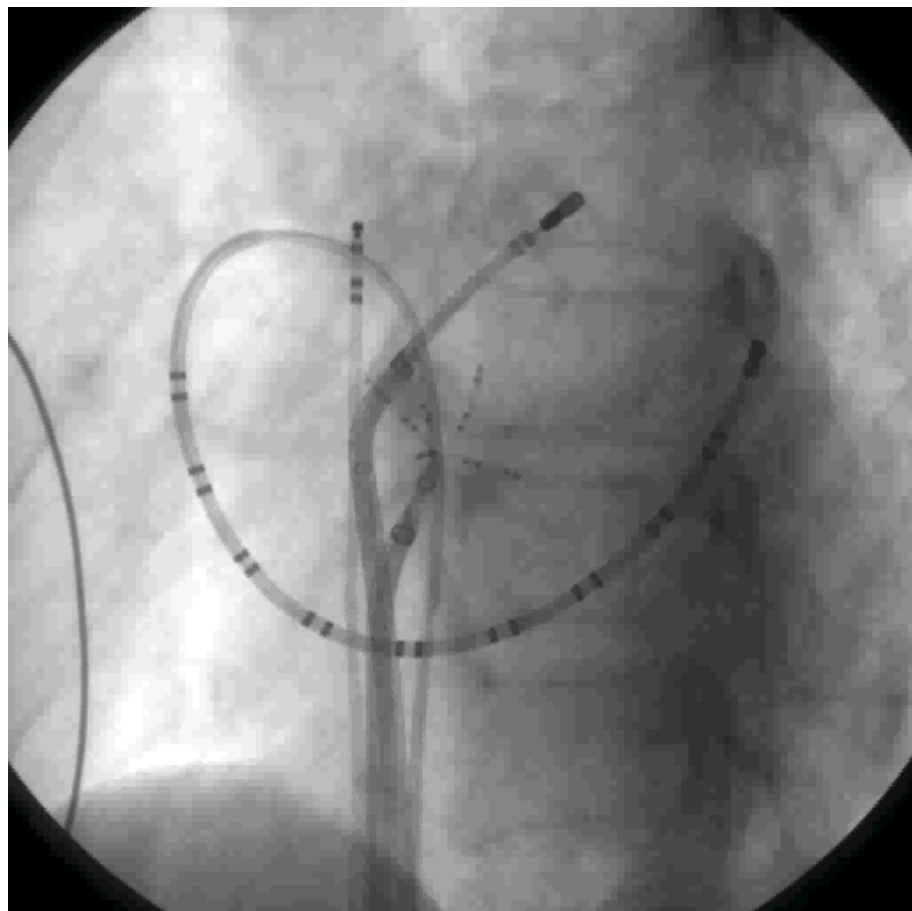
NSR (Post ablation)



# Ablation 1

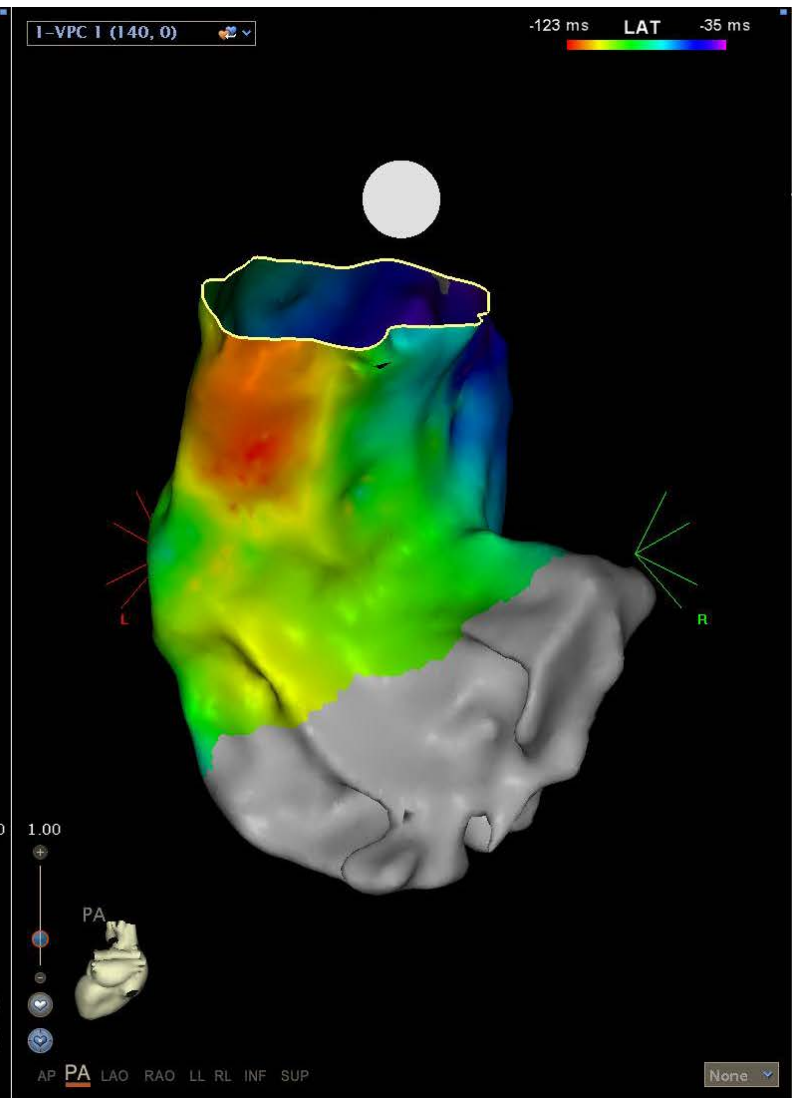
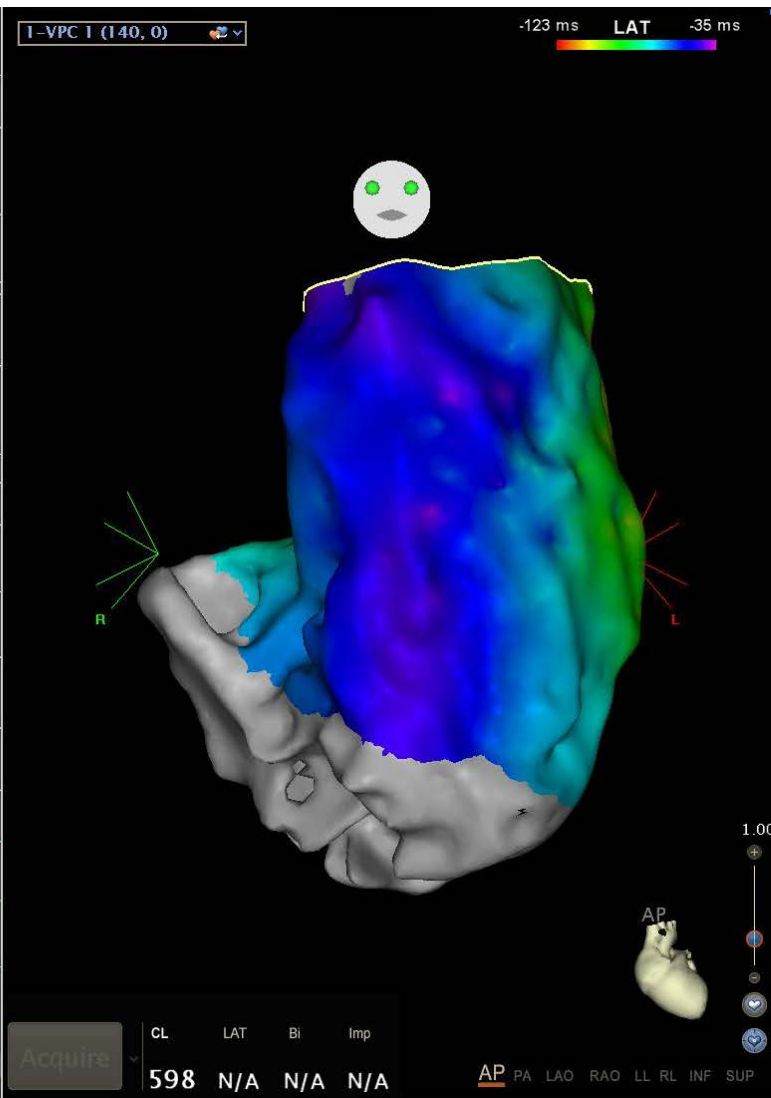
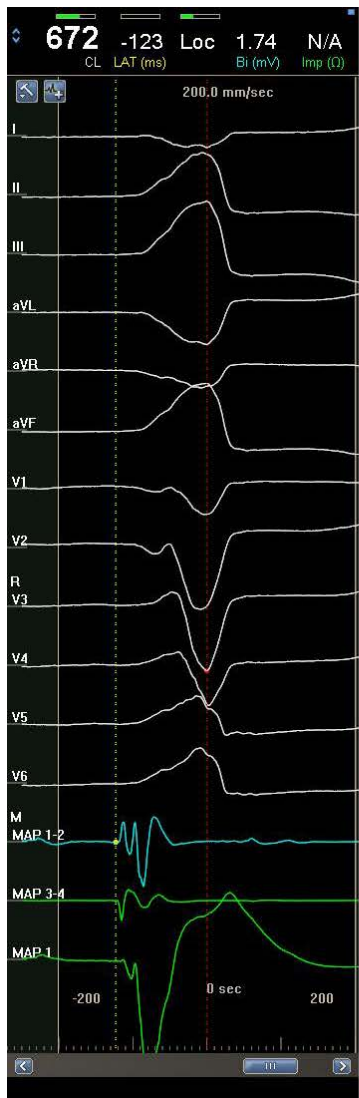


# Ablation 2

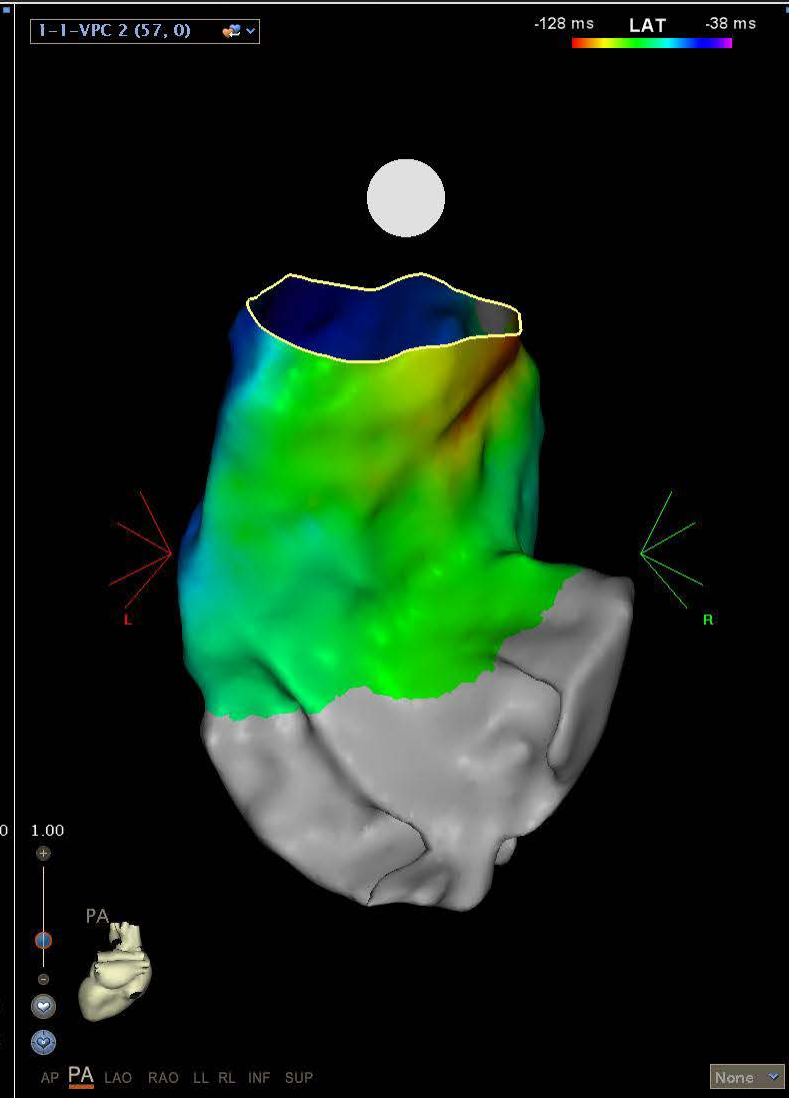
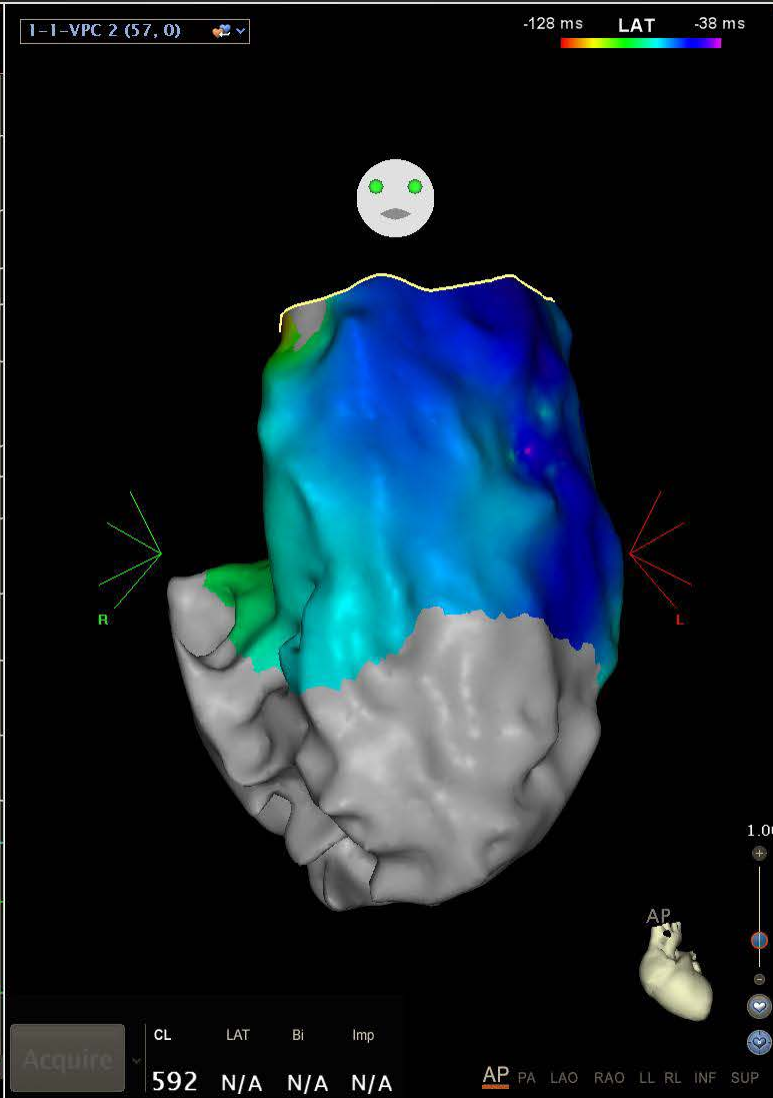
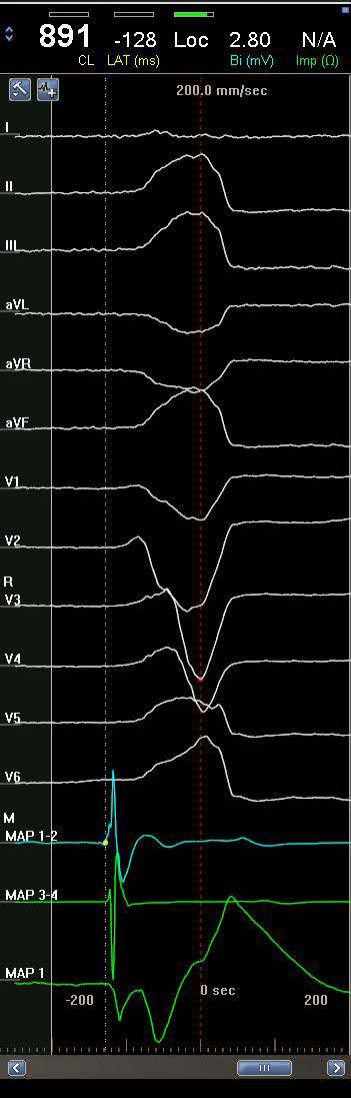




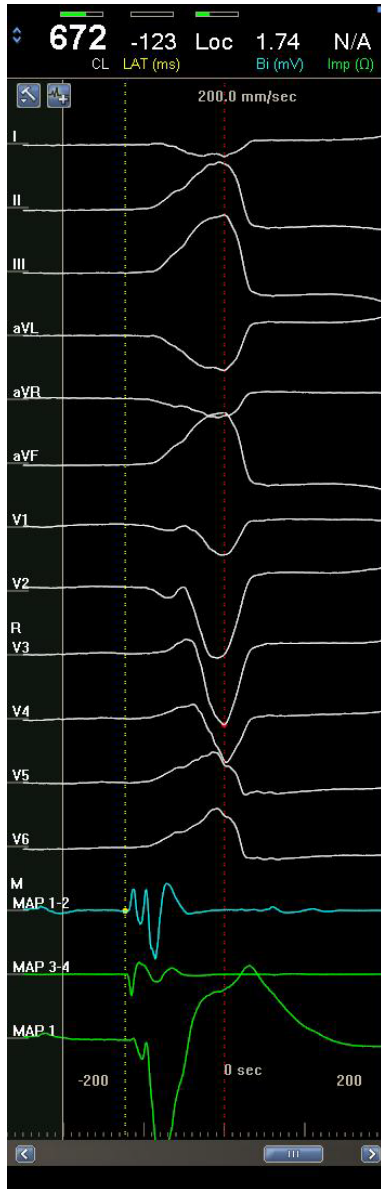
# VPC\_1



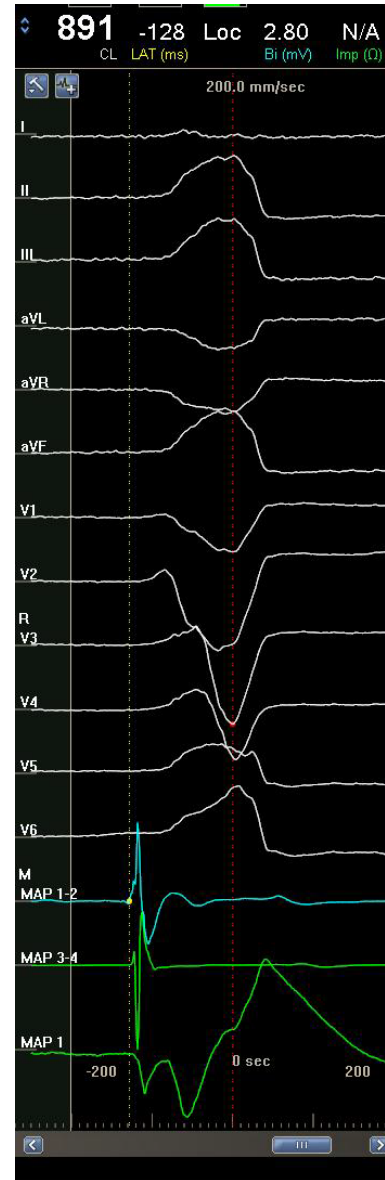
# VPC\_2



# Signal



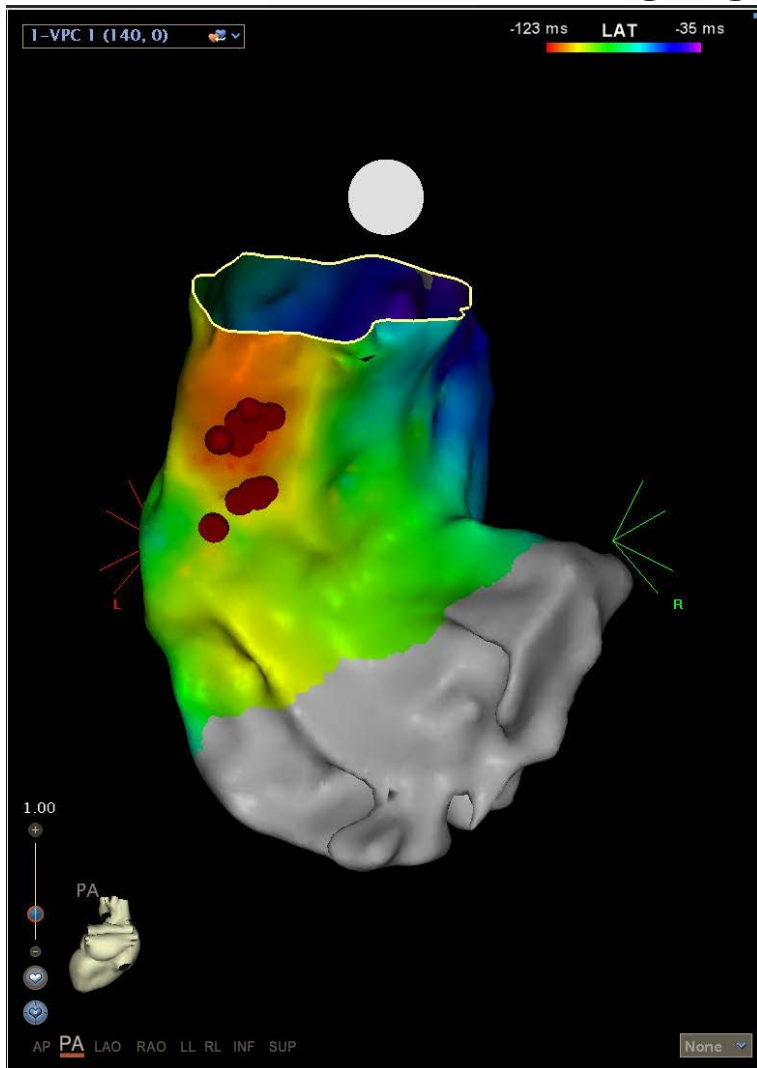
VPC 1



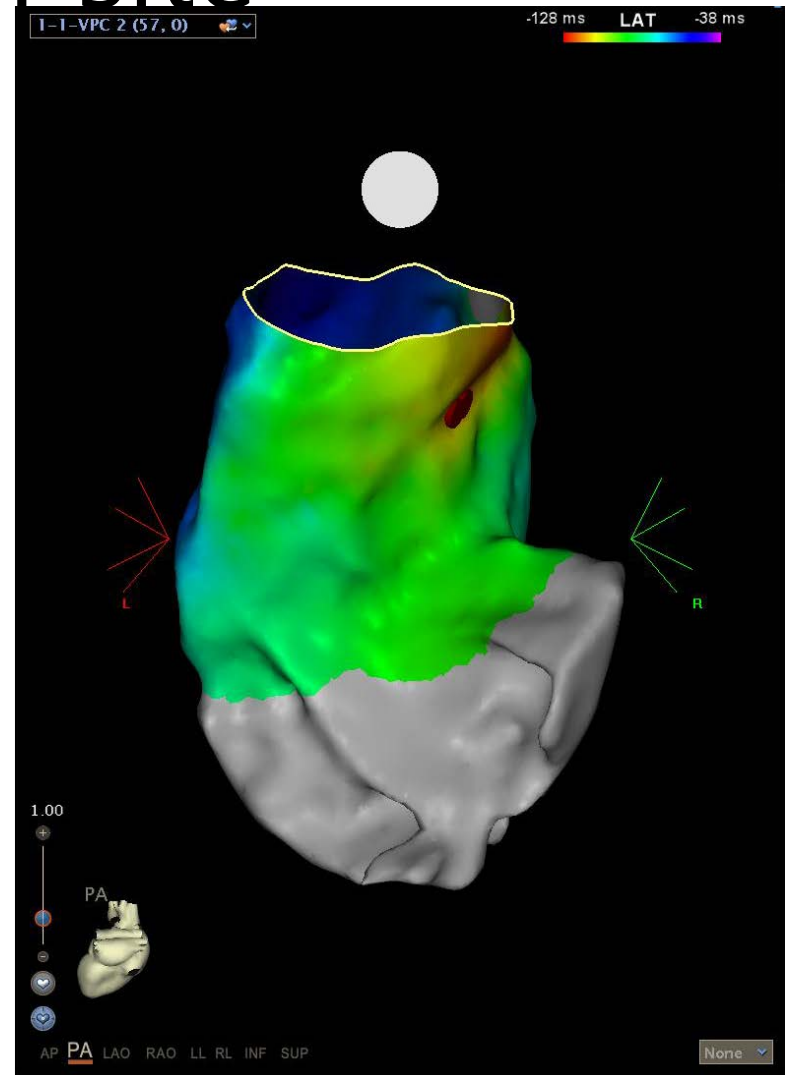
VPC 2



# Ablation site



VPC 1



VPC 2

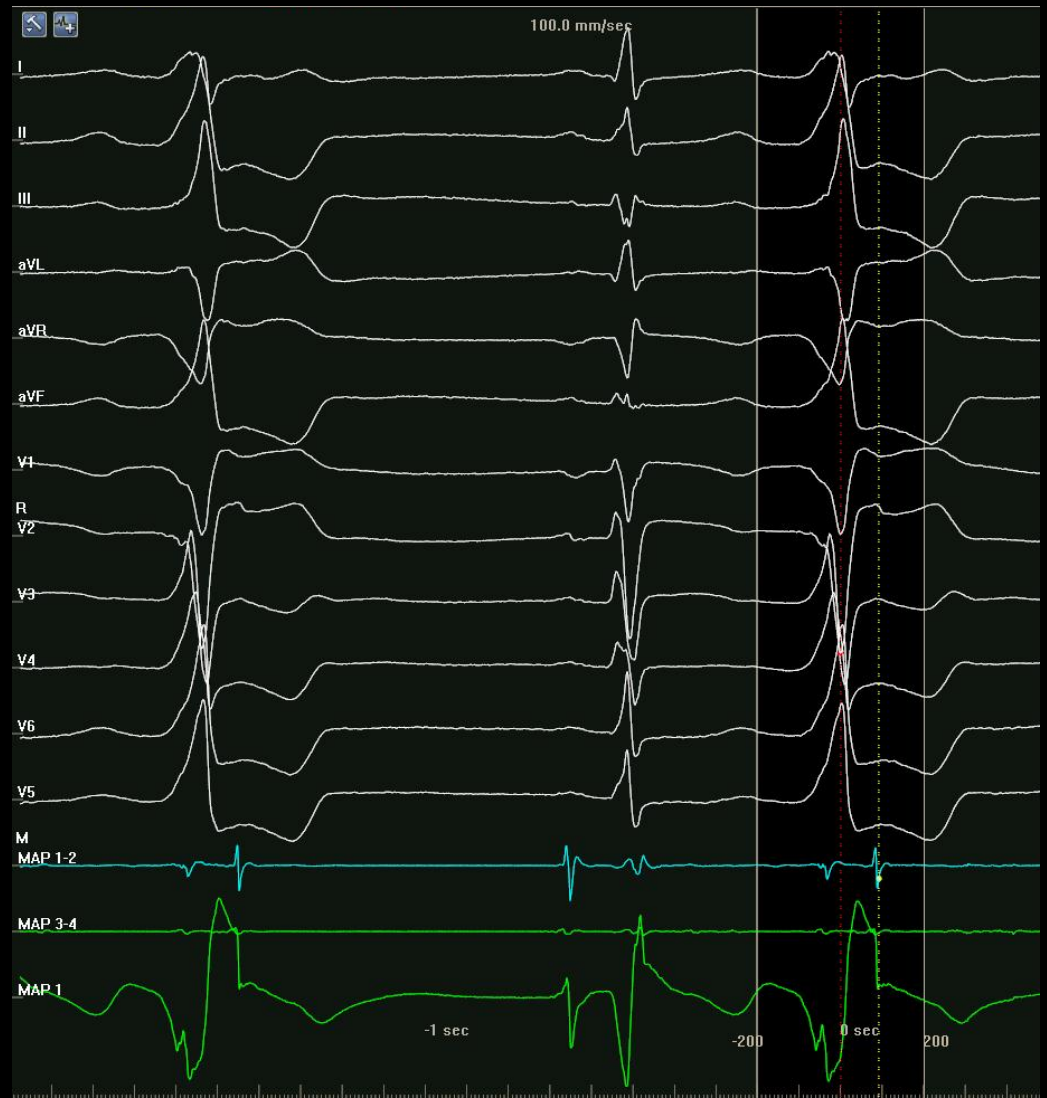
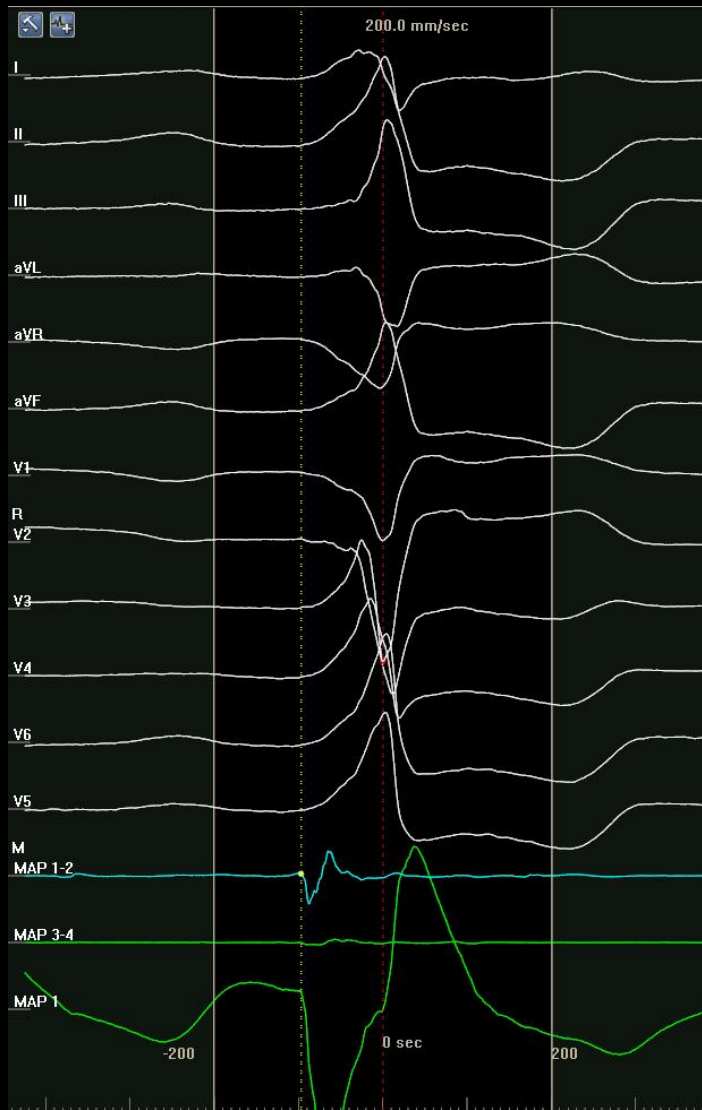
# Case 2

- 22세 남자
- OT VT 로 catheter ablation
  - 당일 저녁에 재발
- 다음날 재시술



**CARTO<sup>3</sup>**  
SYSTEM

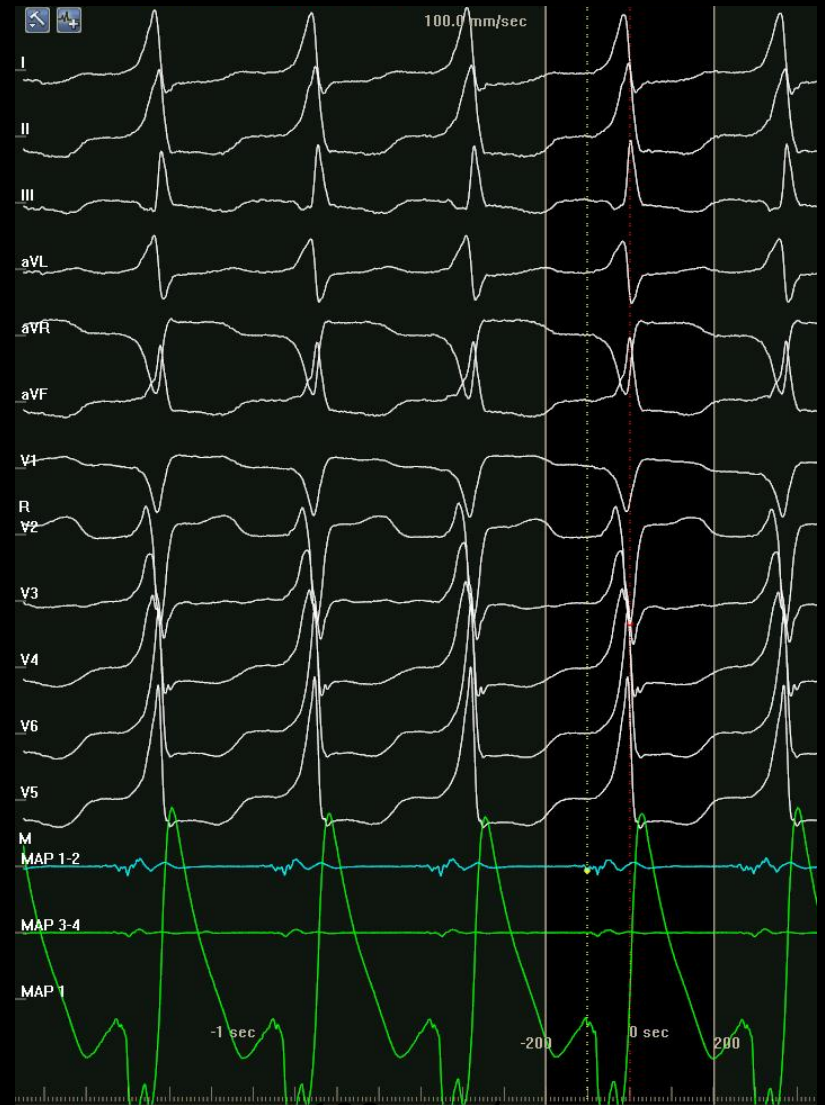
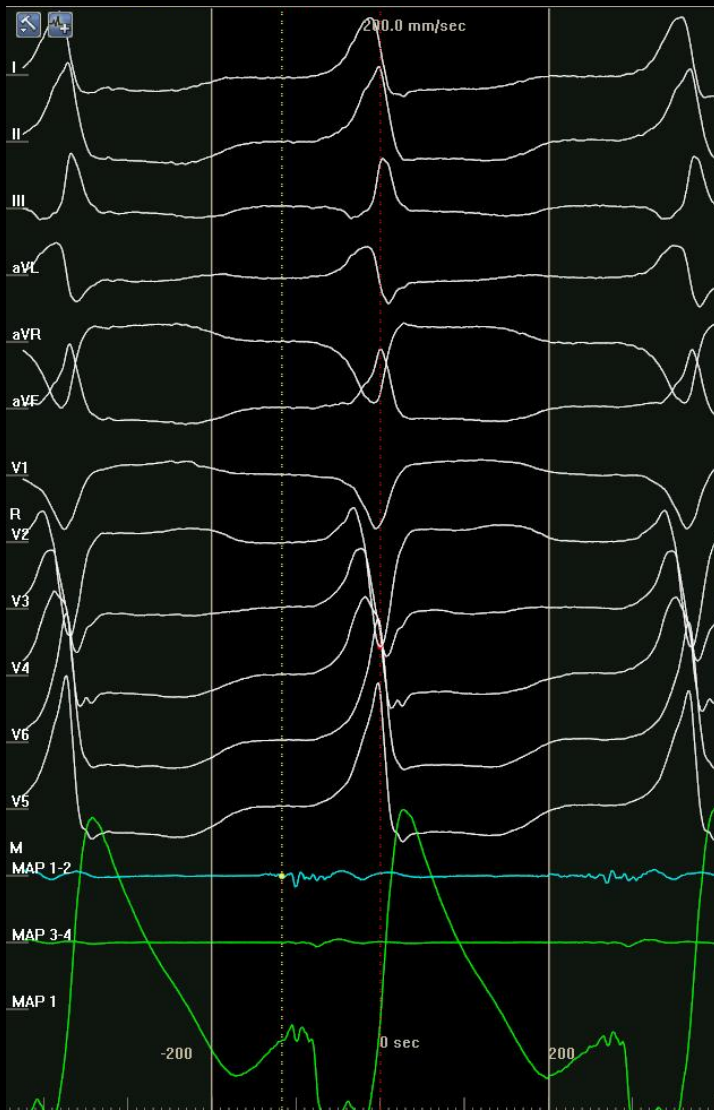
| 1<sup>st</sup> VPC

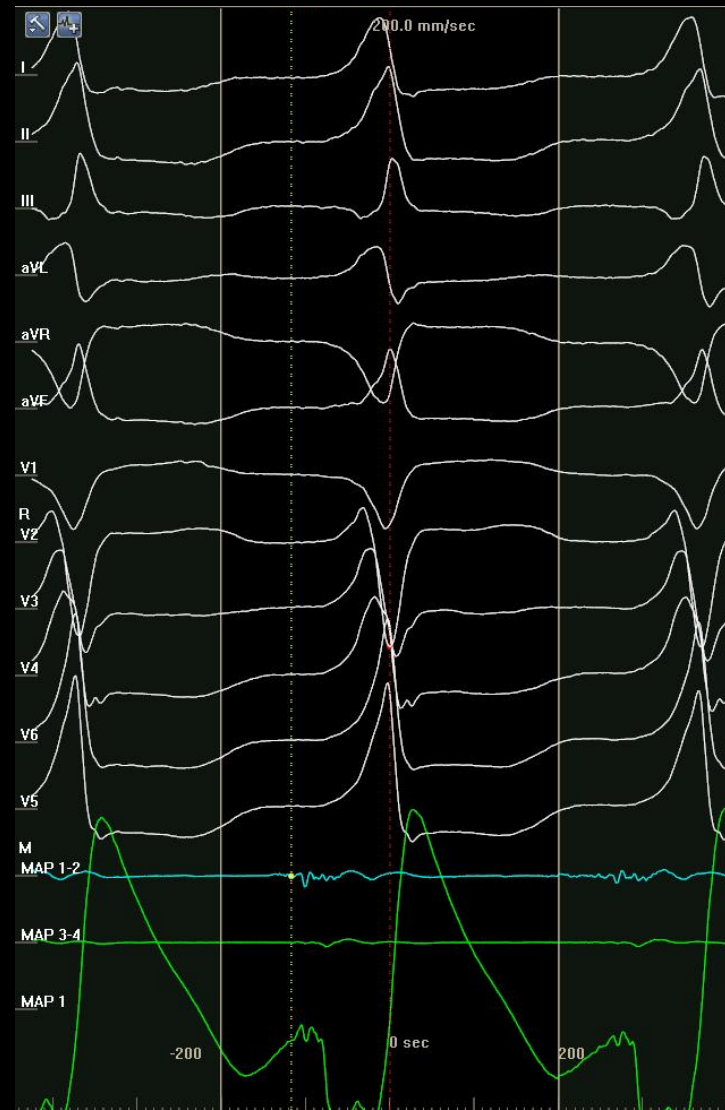
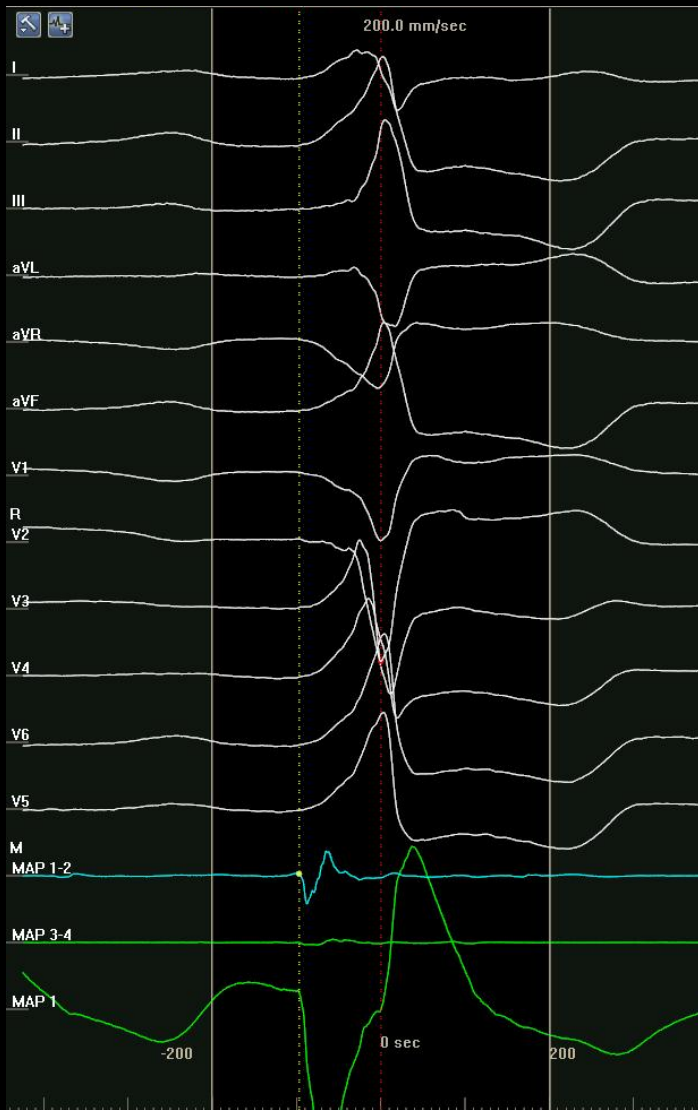






# CARTO<sup>3</sup> SYSTEM | 2<sup>nd</sup> VT

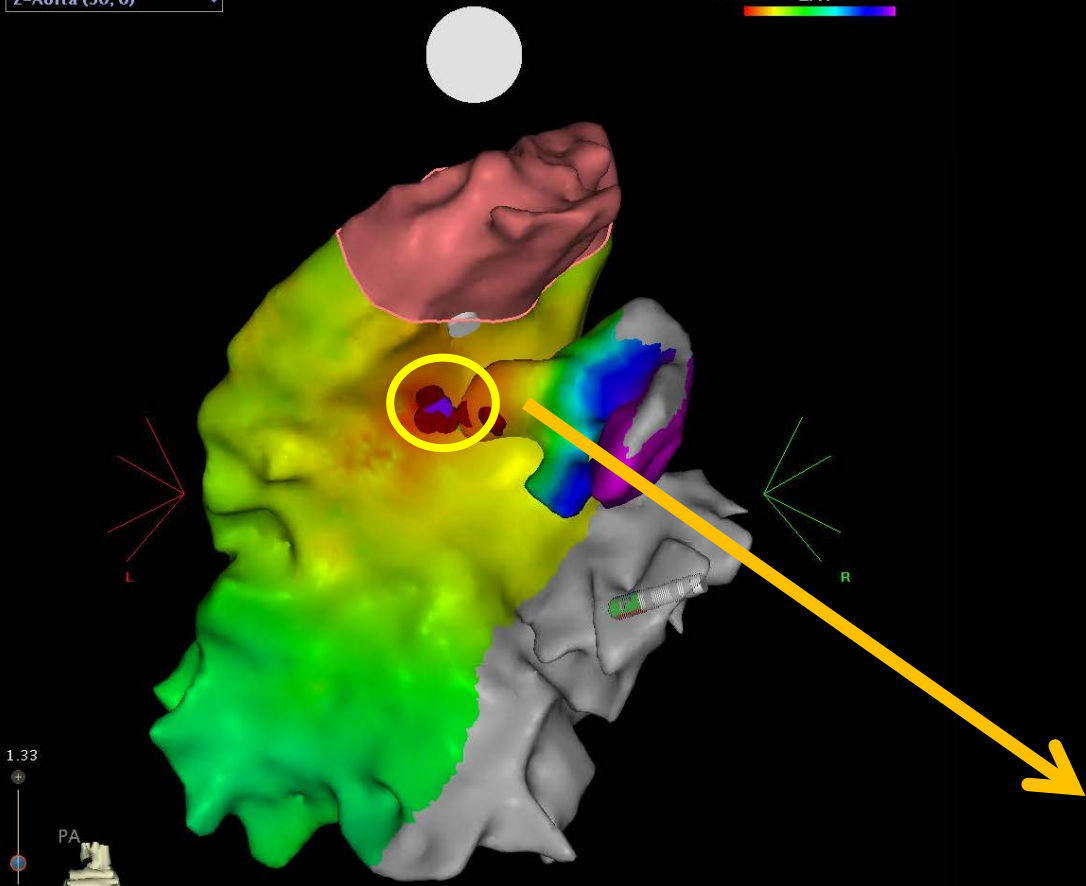






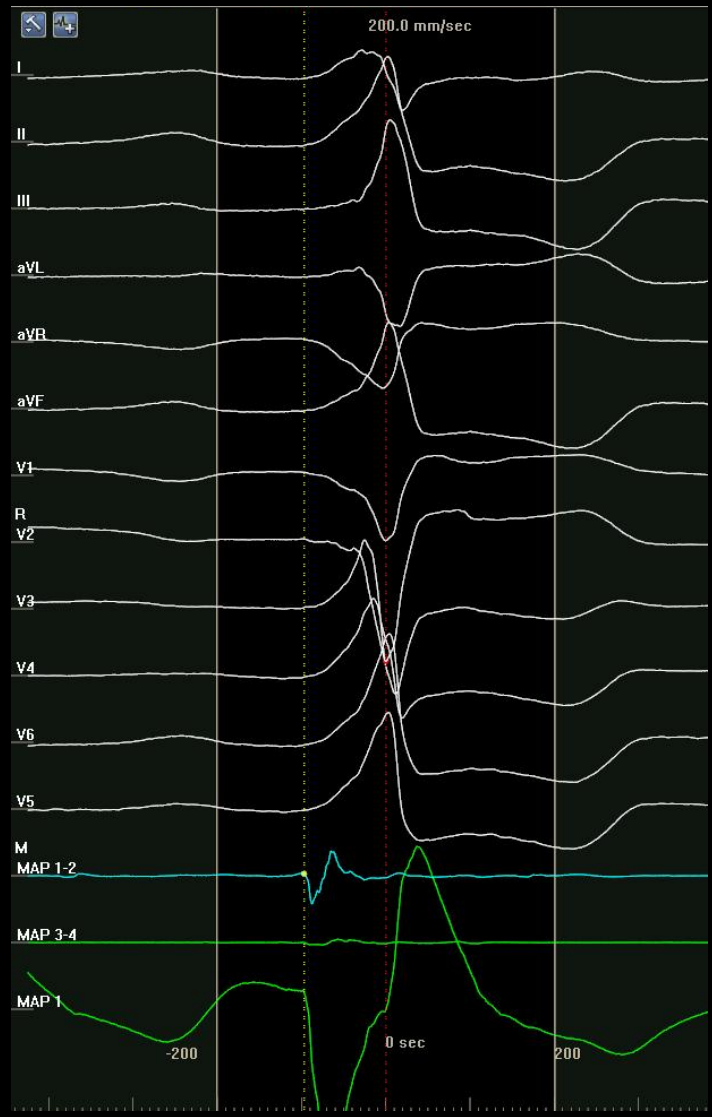
2-Aorta (30, 0)

-111 ms LAT 92 ms

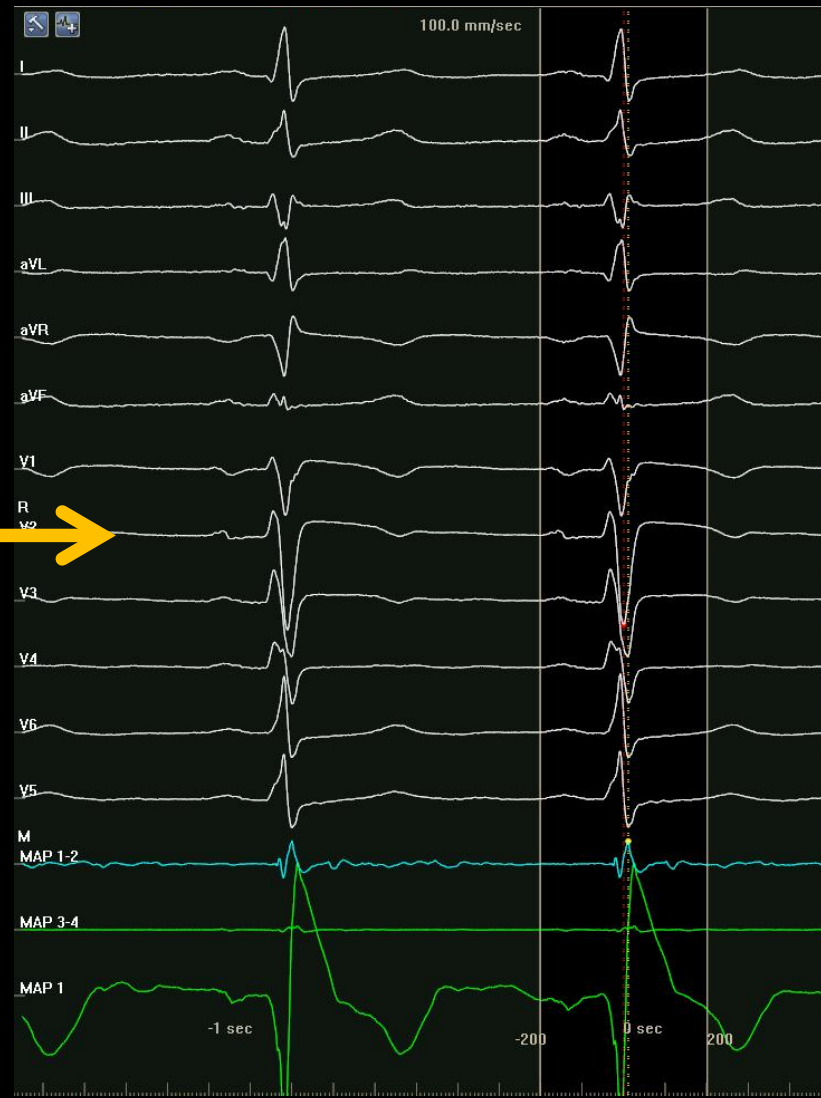
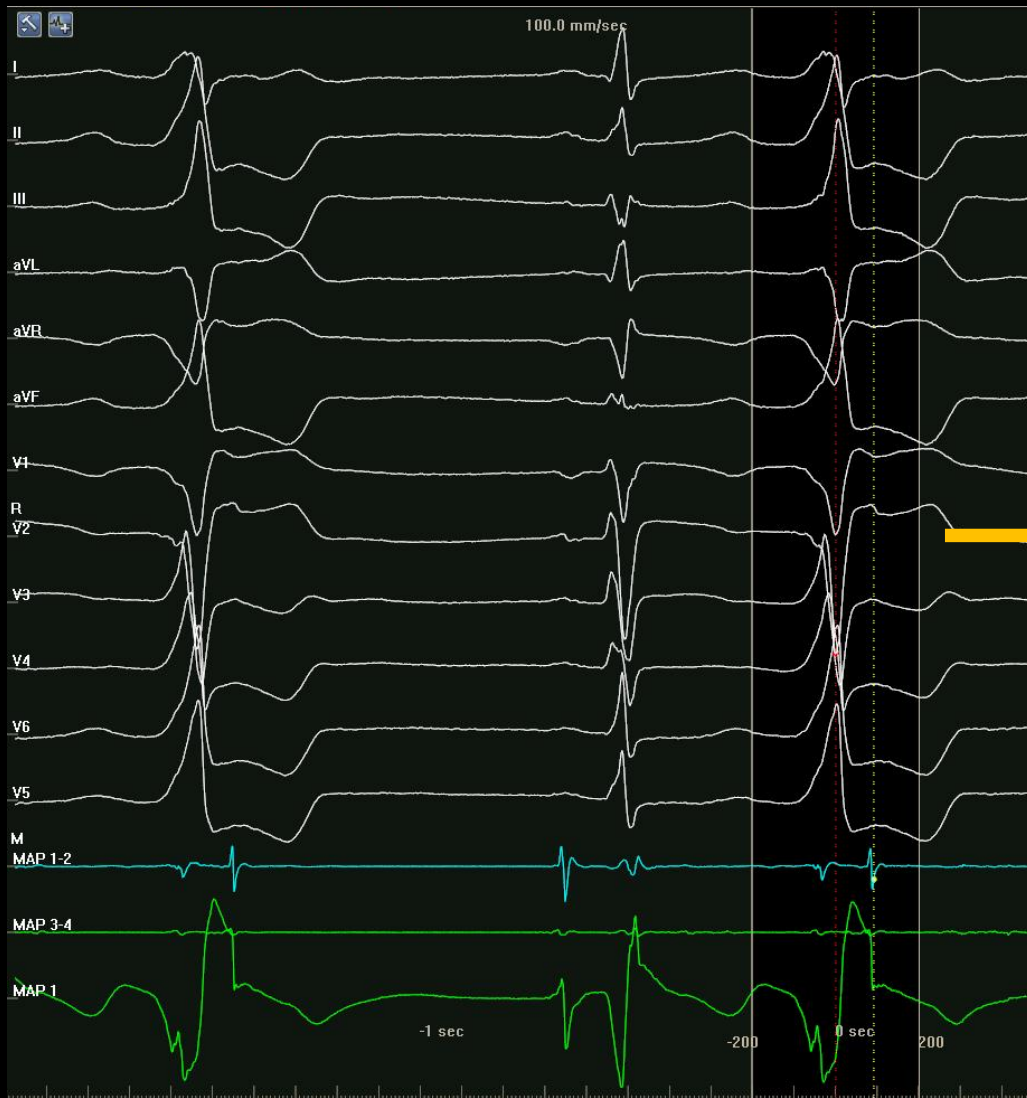


1.33  
PA  
AP PA LAO RAO LL RL INF SUP

Visu Tac







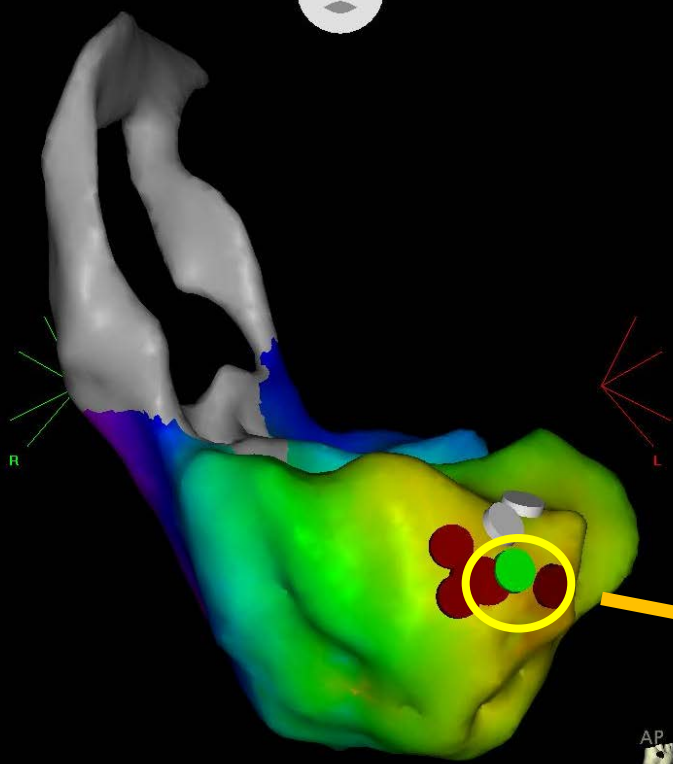


**CARTO<sup>3</sup>**  
SYSTEM

# 2<sup>nd</sup> VT \_ earliest site

3-Aorta redu (144, 0)

-125 ms **LAT** 17 ms



Acquire	CL	LAT	Bi	Imp
	1058	N/A	N/A	N/A

AP PA LAO RAO LL RL INF SUP



